

뇌신경재활

게시일시 및 장소 : 10 월 19 일(토) 08:30-12:30 Room G(3F)

질의응답 일시 및 장소 : 10 월 19 일(토) 11:00-11:30 Room G(3F)

P 3-77

Recovery of ideomotor apraxia and superior longitudinal fasciculus injury in a stroke patient

Jeong Pyo Seo^{1†}, Jang Sung Ho^{1†}, Jun Young Kim^{1*†}

College of Medicine, Yeungnam University, Department of Rehabilitation Medicine¹

Objectives

No previous study has reported on the recovery of an injured superior longitudinal fasciculus (SLF). In this study, we report on a stroke patient who showed recovery of ideomotor apraxia (IMA) concurrent with recovery of an injured SLF as demonstrated by serial diffusion tensor tractography (DTT).

Methods

A 50-year-old male patient presented with right hemiparesis at the onset of an infarct in the left middle cerebral artery territory. At two weeks after infarct onset, he started rehabilitation and exhibited appropriate response to instruction and an intact ideational plan for motor performance; however, he was uncheckable on Mini-Mental State Examination and showed global aphasia (aphasia quotient 12th percentile) on the Western Aphasia Battery. During 3 weeks of rehabilitation, his ideomotor apraxia test score improved from uncheckable at two weeks after onset to full score at five weeks after onset (full score: 40, cut-off value: 32). On DTT at 2-weeks post-onset, the left SLF fibers showed injury at the inferior parietal lobule (IPL) area. By contrast, the injured left SLF was elongated to the left IPL area on 5-week DTT. In addition, the voxel number of the left SLF was higher on 5-week DTT than on 2-week DTT.

Conclusion

Recovery of an injured SLF concurrent with recovery of IMA was demonstrated in a patient with cerebral infarct. We believe that the recovery of an injured left SLF is an IMA recovery mechanism in patients with brain injury.

Acknowledgment :This research was supported by Basic Science Research Program through the National Research Foundation of Korea(NRF) funded by the Ministry of Education (NRF-2016R1A6A3A11933121)

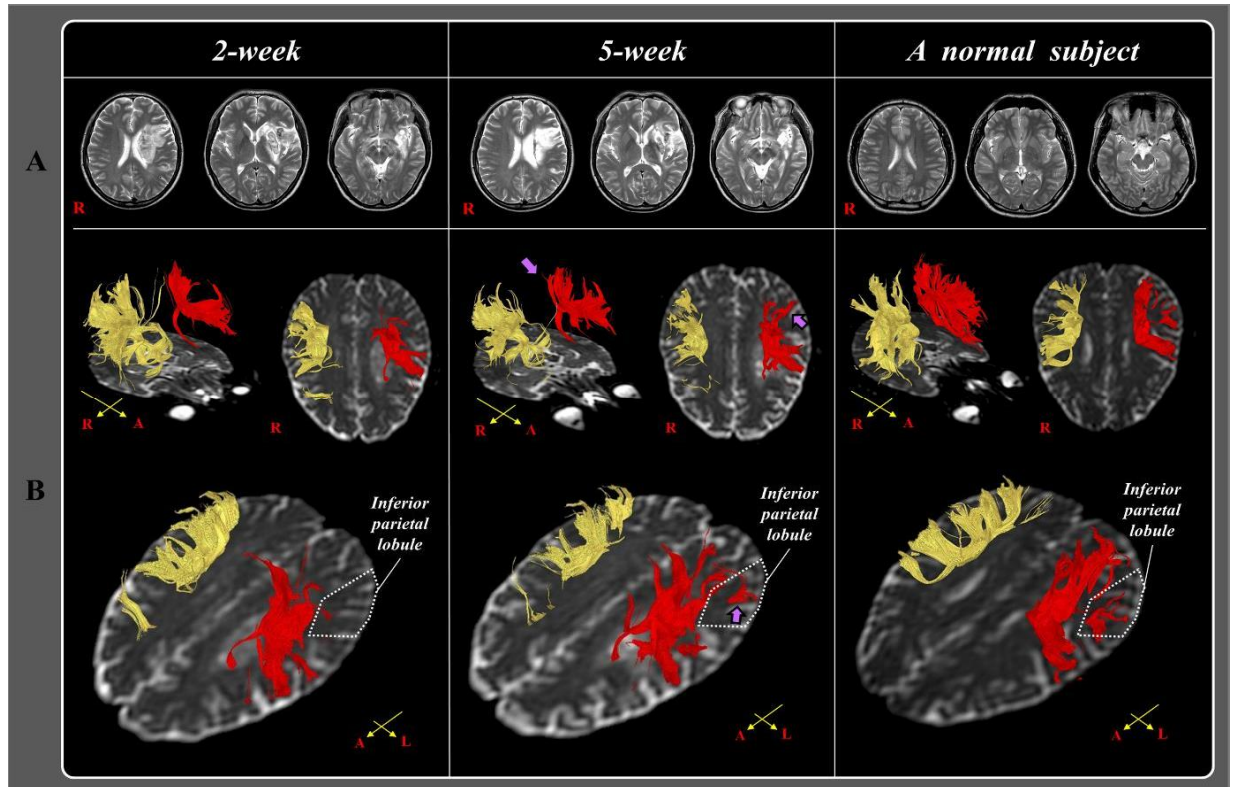


Fig 1. T2-weighted brain MR images at two weeks and five weeks after onset show leukomalactic lesions in the left middle cerebral artery territory. B: Results of diffusion tensor tractography (DTT). The left superior longitudinal fasciculus (SLF) shows injury in the inferior parietal lobule (IPL) area on 2-week DTT. By contrast, the injured left SLF extends to the left IPL area on 5-week DTT (purple arrows)